

## GIST in Pregnancy: A Rare Case of Hematemesis

Joylene D'Almeida\*, Prema DCunha\*\*

### Abstract

*Gastric cancers are very rare in pregnancy and are often undiagnosed due to lack of referral of symptomatic patients to speciality centres from the peripheral units. Though the general outcomes are poor, a favourable prognosis can be ensured with early diagnosis and curative therapy. All that is required is a strong clinical suspicion and a prompt endoscopic evaluation of gastric symptoms in pregnancy.*

**Keywords:** Hematemesis; Gastric tumour; Pregnancy.

### Introduction

Gastric cancers in pregnancy are very rare and over all have a poor prognosis. The unfavourable outcome can be attributed to the delay in diagnosis. This can be due to misinterpretation of G I symptoms as variations of pregnancy symptoms and hesitating to do an early and prompt upper G I endoscopy to evaluate the same.

The etiopathogenesis of the GIST in pregnancy is debatable. Researchers suggest that environmental factors, genetic and pregnancy with hormonal influences, itself could be etiological contributors. We present the case report of a 26 year old gravida two who presented to the emergency with acute episodes of hematemesis and severe anemia. She was diagnosed to have a Gastric tumour (GIST) on abdominal sonography and endoscopic evaluation. She recovered well after surgical

treatment and chemotherapy. This case reinforces the importance of evaluating G I symptoms in pregnancy with a prompt endoscopy.

### Case Report

A 26 year old lady who was a gravida two with a previous live healthy baby, presented to the emergency with hematemesis since 3 days. The vomitus was dark red and contained food particles. She had been referred to our tertiary centre from the periphery as a case of severe anemia with hematemesis. She also complained of giddiness and melena since one week. She didn't however have any abdominal pain or constipation, her past surgical and medical history was unremarkable.

In her previous pregnancy 3 years back, she has an uneventful antenatal period and had no medical or surgical complications during the same.

On examination, she demonstrated severe degree of pallor and mild tachycardia. Her other vitals and systems were normal. On examining her abdomen was found to be non-tender with a relaxed gravid uterus of 32 weeks size with a regular fetal heart.

Her hematologic evaluation revealed haemoglobin of 3.9g/dl and an Hct of 11.8. Her total count was elevated to 24,000. Coagulation profile, liver functions and electrolytes were normal.

An obstetric ultrasound revealed single live intra uterine fetus of 32 weeks of growth. On further evaluation the abdomino pelvic scan showed a 7x5cm well defined heterogeneous solid lesion in relation to the posterior wall of stomach and was present anterior to the pancreas. Ultrasound gave the final impression of a well defined heterogeneous solid lesion 7x5 cm in the

\*Assistant Professor,  
Department of Obstetrics  
and Gynaecology,  
\*\*Department of  
Oncosurgery  
Father Muller Medical  
college, Mangalore

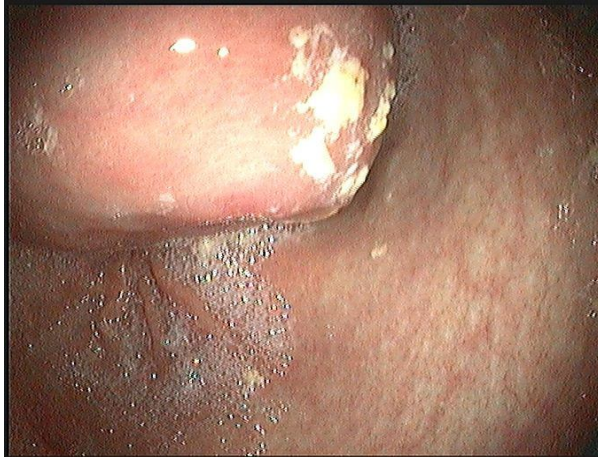Dr. Joylene Diana  
DAlmeida, DAL Villa,  
Jeppu Bappal First Cross,  
Kankanady, Mangalore -  
575002

E-mail :  
joylene16@yahoo.com

posterior wall of the stomach suspected to be a GIST (Gastrointestinal stromal tumour).

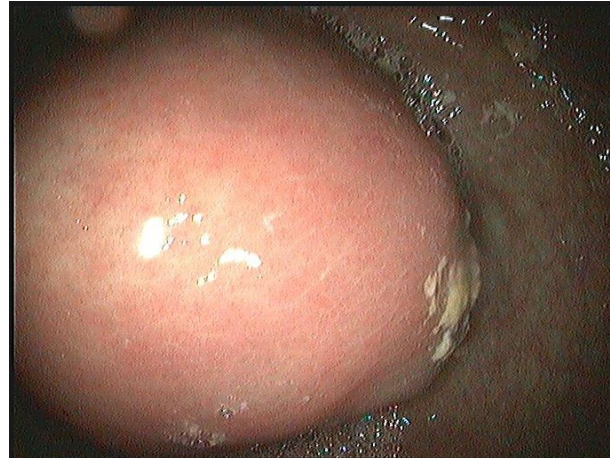A prompt upper GI endoscopy demonstrated a large sub-mucosal lesion with a central ulcer (with features of recent bleed) in the mid and distal part of the corpus in the posterior wall of stomach. Esophagus and duodenum were normal and the final gastroscopic diagnosis was a GIST.

**Fig. 1:** Large sub-mucosal lesion with central ulceration arising in the posterior wall of the stomach



Treatment ensued and she was transfused with 2 units of packed cells on day one and went on to receive 3 more units over the subsequent three days. She was kept under regular hematologic and fetal surveillance. Her haemoglobin level showed fluctuations despite blood transfusions.

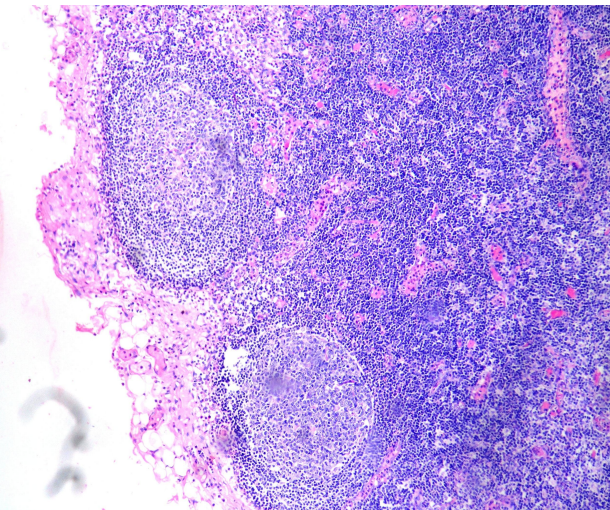
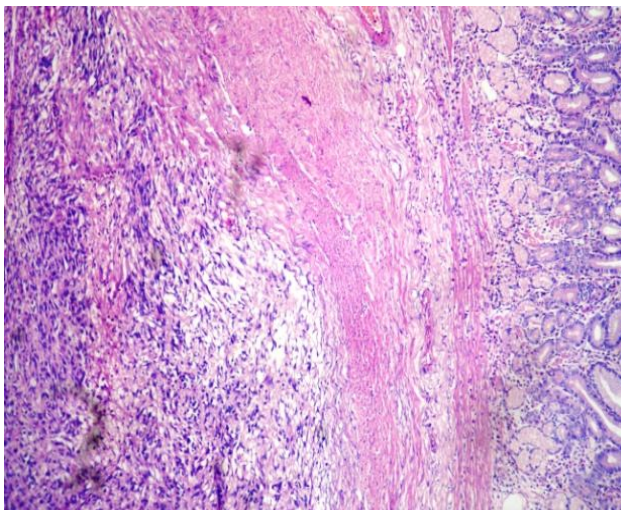
**Fig. 2:** Sub-mucosal lesion



On day 11, patient underwent an elective caesarean section at 34 weeks by midline abdominal incision and delivered a healthy male baby weighing 2.170 kg. The surgery was continued by the oncosurgeons, midline incision extended. On opening a tumour nodule of around 8 cm was found in the posterior wall of stomach along the lesser curvature. Procedure performed was a billroth two reanastomosis – partial gastrectomy with gastrojejunostomy with jejunajejunostomy. Tumour with stomach wall was sent for histopathology and c kit CD 117.

Patient recovered well postoperatively with good wound healing. The histopathology of the resected tumour showed stromal tissue infiltrating the submucosa, sparing the mucosa and the serosa intact. Resected gastric lymph nodes were free of tumour.

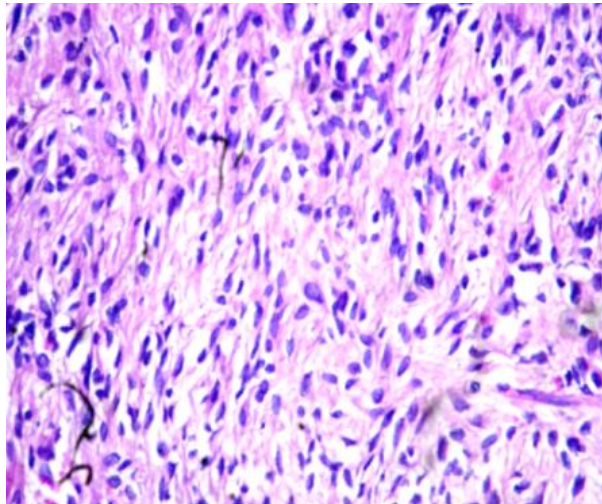
**Fig. 3:** (a) Cellular proliferation of bland spindle cells with pale to eosinophilic fibrillar cytoplasm. (b) Cells in whorls or short intersecting fascicles, with frequent and prominent nuclear palisading, numerous perinuclear vacuoles. (c) Minimal pleomorphism; < 2 mitotic figures/50 HPFs



CD 117 was strongly positive, hence confirming the diagnosis of GIST in pregnancy. Our patient was

classified with an intermediate risk and was treated with the immune modulating drug Imatinib.

**Fig. 4:** Uniform spindle cells Pale eosinophilic, indistinct cytoplasm Oval to short spindled nuclei Frequently palisades May have paranuclear vacuoles



## Discussion

Gastric carcinoma in pregnancy is very rare, seen only in 5 % of patients less than 40 years. It is even more so in pregnancy. It accounts for about 0.01% of all cases [1]. In our case the patient presented acute hematemesis, at 26 years of age in her second pregnancy, with no personal or family history of G I disease.

In patients under 40 years of age, it is found to be more common in females and more aggressive, with a male: female ratio of 1:1.5. Younger the age of presentation, more Aggressive is the tumour and poorer the differentiation [2].

Furukawa et al, in his study of 64 pregnant patients with gastric cancer concluded that the immunosuppressive effect of pregnancy accelerates the development of gastric cancer [3].

Patients presenting with Gastric cancer in pregnancy have an overall poor prognosis. This can be attributed to the following:

1. Advanced stage of presentation of the Malignancy in pregnant patients, due to lack of awareness.
2. Physicians neglecting upper G I symptoms, considering them as normal pregnancy variants.
3. Hesitancy to pursue an upper G I endoscopy for evaluation of the above.

Our patient presented with acute hematemesis and did not have other gastrointestinal symptoms or weight loss that has been reports by many authors. A Strong clinical suspicion was present that led to prompt evaluation. Referral to a speciality centre from

peripheral units, a prompt G I endoscopy and clinical suspicion, ensured early treatment and favourable outcome in our case. Endoscopic evaluation is safe in pregnancy and is recommended for atypical and refractory G I symptoms.

Treatment of Gastric carcinoma in pregnancy also includes providing a favourable fetal outcome if feasible and hence depends on the gestational age of presentation.

Our patient presented at 32 weeks and 4 days and underwent an elective CS at 34 weeks, ensuring a favourable fetal prognosis.

Factors influencing treatment decision include: Maternal condition, need for surgery, chemotherapy and fetal prognosis based on gestational age.

Gastric tumours should be considered when a patient presented with hematemesis and refractory nausea, vomiting and epigastric discomfort beyond 16 weeks of pregnancy.

The overall prognosis in gastric cancer is poor [4], 80% die in the first year and 3-year survival rate is 8%. In a Japanese review of 61 patient with gastric cancer diagnosed in pregnancy, 96.7% were advanced with low respectability at 47.5%. The hospital mortality was 22.7% in those who had resection and overall prognosis was poor three- year survival at 21.1%. Therefore early recognition and diagnosis is critical.

During pregnancy, in case of operable tumors, surgical modality of therapy is pursued at the appropriate gestational age for fetal survival. In inoperable cases, chemotherapy is the treatment of choice with due fetal consideration.

In our case study, concurrent gastric surgery (billroth two) with caesarean section was carried out. A healthy male baby was delivered. Further management included chemotherapy with the imatinib, an immune modulating chemotherapeutic agent.

There is a need for further study of the natural history of gastric cancer in pregnancy. However Gastric tumours should be considered in the differential diagnosis of G I Symptoms in pregnancy and reflexively prompt an endoscopic evaluation.

## References

1. Silverberg E, Lubera J. Cancer statistics, 1989. *Cancer* 1989; 39: 3-20.
2. Jaspers VKI, Gillissen A, Quakernack K. Gastric cancer in pregnancy: Do pregnancy, age or female

- sex alter the prognosis? Case reports and review. Eur J Obstet Gynecol Reprod Biol 1999; 87: 13-22.
3. H. Furukawa, T. Iwanaga, M. Hiratsuka et al., "Gastric cancer in young adults: growth accelerating effect of pregnancy and delivery," Journal of Surgical Oncology, 1994; 55(1): 3-6.
  4. H. Ueo, Y. Okudaira, and M. Hirabayashi, "Gastric cancer associated with pregnancy. A case report of early gastric cancer and review of 100 cases in Japan," Journal of the Japan Society of Clinical Surgery, 1989; 50: 312-318.
- 

*Introducing a new sister concerned company of **Red Flower Publication Pvt. Ltd.***

**RF Library Services Pvt. Ltd.**

**RF Library Services Pvt. Ltd.** is a global market leader in managing professional information. We develop and deliver innovative services that enable the use of knowledge to its full extent. As the only information Service Company globally we play a key role in today's complex information marketplace. Founded in 1985 as a registered company under sub-section (2) of section 7 of the Companies Act, 2013 and rule 8 of the Companies (Incorporation) Rules, 2014, the business draws on more than a decade of experience within the information industry. With this knowledge, we satisfy the needs of thousands of customers from over 30 countries. We are a division of Red Flower Publication Pvt. Ltd.

*Where we are based?*

RF Library Services Pvt. Ltd is located in Delhi-91 in India.

**RF Library Services Pvt. Ltd.**

D-223/216, Laxmi Chambers, Laxmi Nagar,  
Near Laxmi Nagar Metro Station,  
Delhi-110092(India)

Tel: 011-22756995, Fax: 011-22756995

E-mail: rflibraryservices@vsnl.net, rflibraryservices@gmail.com

Website: [www.rf-libraryservices.com](http://www.rf-libraryservices.com)